

Consensus Statement of Definitions for Anorectal Physiology Testing and Pelvic Floor Terminology (Revised)

Liliana G. Bordeianou, M.D., M.P.H. • Joseph C. Carmichael, M.D. • Ian M. Paquette, M.D.
Steven Wexner, M.D., Ph.D.(Hon.) • Tracy L. Hull, M.D. • Mitchell Bernstein, M.D.
Deborah S. Keller, M.D. • Massarat Zutshi, M.D. • Madhulika G. Varma, M.D.
Brooke H. Gurland, M.D. • Scott R. Steele, M.D.

Prepared on behalf of the Pelvic Floor Disorders Committee and the Clinical Practice Guidelines Committee of The American Society of Colon and Rectal Surgeons

The American Society of Colon and Rectal Surgeons (ASCRS) is dedicated to ensuring high-quality patient care by advancing the science, prevention, and management of disorders and diseases of the colon, rectum, and anus. This Clinical Practice Guidelines Committee is charged with leading international efforts in defining quality care for conditions related to the colon, rectum, and anus by developing Clinical Practice Guidelines based on the best available evidence. These guidelines are inclusive, not prescriptive, and are intended for the use of all practitioners, healthcare workers, and patients who desire information about the management of the conditions addressed by the topics covered in these guidelines. Their purpose is to provide information on which decisions can be made rather than to dictate a specific form of treatment.

It should be recognized that these guidelines should not be deemed inclusive of all proper methods of care or exclusive of methods of care reasonably directed toward obtaining the same results. The ultimate judgment regarding the propriety of any specific procedure must be made by the physician considering all of the circumstances presented by the individual patient.

Funding/Support: None reported.

Financial Disclosure: None reported.

Correspondence: Scott R. Steele, M.D., 9500 Euclid Ave, A30, Cleveland, OH 44915. E-mail: SteeleS3@ccf.org

Dis Colon Rectum 2018; 61: 421–427
DOI: 10.1097/DCR.0000000000001070
© The ASCRS 2018

DISEASES OF THE COLON & RECTUM VOLUME 61: 4 (2018)

STATEMENT OF THE PROBLEM

As surgeons work to improve the quality of patient care, it is important that data and results are communicated and compared accurately. For that to happen, the terminology used must be precise and uniform. With medical information increasingly shared, a consensus about the terminology is desirable. The purpose of this document is to define standardized terminology for use in academic presentations and publications pertaining to defecatory pelvic floor disorders.

METHODOLOGY

The ASCRS, the Colorectal Surgical Society of Australia, and the Association of Coloproctology of Great Britain and Ireland have previously published definitions of anorectal physiology terms after consulting with selected experts within each represented society.¹ This revision of the above-mentioned definitions was created at the initiative of the ASCRS Pelvic Floor Disorders Committee and the Clinical Practice Guidelines Committee. The Pelvic Floor Disorders Committee is composed of members who are chosen because they have demonstrated expertise in the care and treatment of pelvic floor conditions. This committee was created to lead international efforts in defining quality care for conditions related to the pelvic floor. Once approved by the Pelvic Floor Disorders Committee, the document was also reviewed in detail by the ASCRS Clinical Practice Guidelines Committee, which is charged with developing clinical practice guidelines and definitions based on the best available evidence.

Although great effort and care have gone into the process, it is recognized that the terminology will evolve with its use and future advances in surgical knowledge. A

process for review and refinement will be instituted. In addition, terms from other areas of colon and rectal surgery will be added if these definitions are found to be useful.

DEFINITIONS

Definitions of Functional Bowel and Pelvic Floor Disorders

Anismus

Anismus is failure of striated muscles of the pelvic floor (puborectalis and external anal sphincter) to relax appropriately during attempted defecation. It may be suspected clinically in patients presenting with obstructed defecation syndrome, but the diagnosis needs to be additionally confirmed on anal EMG, anorectal manometry, and/or defecography. Anismus can manifest as either simple nonrelaxation of the puborectalis, or, in extreme cases, as paradoxical contraction of the puborectalis (instead of relaxation) during evacuatory effort.

Anismus can be additionally categorized into 4 types on anorectal manometry based on patient ability to generate adequate pushing force and the type of sphincter contraction.

- Type 1: The patient can generate an adequate rise in intra-abdominal pressure, yet there is a paradoxical increase in anal sphincter pressures.
- Type 2: The patient is unable to generate an adequate rise in intrarectal pressures and has a paradoxical anal sphincter contraction.
- Type 3: The patient can generate an adequate intra-abdominal pressure but either has absent or incomplete (<20%) anal sphincter relaxation.
- Type 4: The patient is unable to generate an adequate pushing force and demonstrates an absent or incomplete sphincter relaxation.

Constipation

Constipation is a dysfunction of colonic motility and the defecation process, best defined by the Rome IV criteria.² A patient is labeled as having constipation when they present with ≥ 2 of the following symptoms during $\geq 25\%$ of defecations: straining, lumpy or hard stools, sensation of incomplete evacuation, sensation of anorectal obstruction or blockage, relying on manual maneuvers to promote defecation, and < 3 spontaneous bowel movements per week. Additional Rome IV diagnostic criteria specify that, in these patients, loose stools are rarely present without the use of laxatives. Furthermore, Rome criteria suggest that a patient cannot have both the diagnosis of irritable bowel syndrome (IBS) with constipation and functional constipation.

Cul-de-Sac Hernias (Peritoneocele, Enterocele, Sigmoidocele, and Omentocele)

A *cul-de-sac hernia* (peritoneocele) is a protrusion of the peritoneum between the rectum and vagina that does not contain any abdominal viscera. An *enterocele* is a protrusion of the peritoneum between the rectum and vagina containing the small intestine. A *sigmoidocele* is a protrusion of the peritoneum between the rectum and vagina that contains the sigmoid colon. An *omentocele* is a protrusion of the omentum between the rectum and the vagina. These conditions may be internal (only visible on defecography) or external (associated with clinically visible rectocele or rectal prolapse).

Fecal Incontinence

Fecal incontinence is identified as the uncontrolled passage of feces or gas over ≥ 1 month's duration, in an individual of ≥ 4 years of age, who had previously achieved control.

Irritable Bowel Syndrome

IBS is a functional bowel disorder in which patients report recurrent abdominal pain in association with defecation and a disordered bowel habit (ie, constipation, diarrhea, or mix of constipation and diarrhea). IBS is additionally defined by the Rome IV criteria² as recurrent abdominal pain that occurs ≥ 1 day per week in the last 3 months and is associated with ≥ 2 of the following: pain that is related to defecation, associated with a change in frequency of stool, and associated with a change in form (appearance) of stool, with symptom onset ≥ 6 months before diagnosis. IBS is additionally differentiated into IBS with constipation, IBS with diarrhea, IBS with mixed symptoms, and IBS indeterminate based on the type of bowel dysfunction associated with the condition.

Mucosal Prolapse

Mucosal prolapse is a circumferential protrusion of rectal mucosa into or beyond the anal canal.

Obstructed Defecation Syndrome

Obstructed defecation syndrome (ODS) is a subset of functional constipation in which patients report symptoms of incomplete rectal emptying with or without an actual reduction in the number of bowel movements per week. The presence and severity of ODS are suspected and measured by querying patients on the mean time spent on the toilet, number of attempts to defecate per day, use of enemas and laxatives, sensation of incomplete or fragmented defecation, need to strain with defecation, and a report of very hard stools.^{3,4} ODS can coexist with other functional bowel disorders, such as slow transit constipation or IBS. Additional characterization and confirmation of ODS require anorectal manometry and/or anal EMG, as well as defecography. ODS can be caused by either anismus or pelvic organ prolapse (POP).

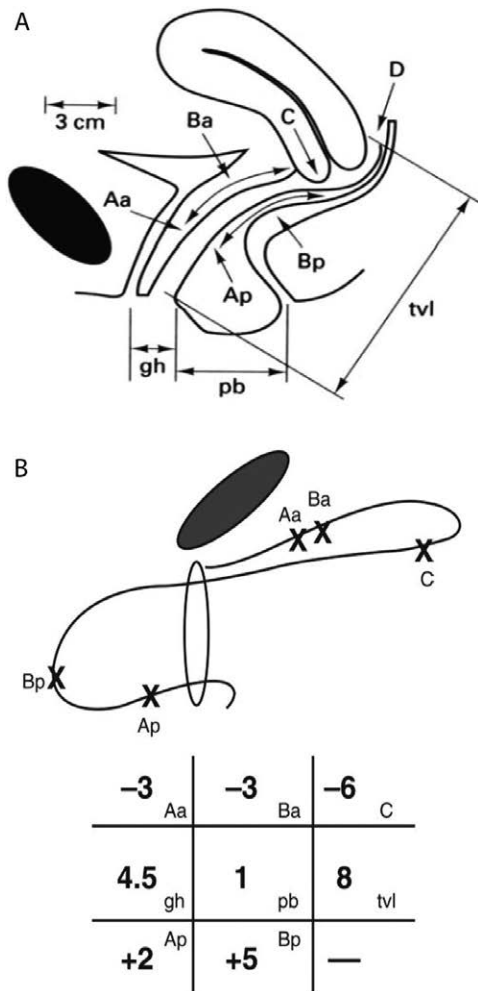


FIGURE 1. A, Points and landmarks for pelvic organ prolapse (POP)-Quantification system examination. Aa = point A anterior; Ap = point A posterior; Ba = point B anterior; Bp = point B posterior; C = cervix or vaginal cuff; D = posterior fornix (if cervix is present); gh = genital hiatus; pb = perineal body; tvl = total vaginal length. B, An example of measurements using the pelvic organ prolapse (POP)-Quantification system. Reprinted with permission from Journal of Medicine and Life 2011;4:75-81.

Pelvic Floor Dysfunction

Pelvic floor dysfunction includes imprecise terminology that does not represent a particular pelvic floor disorder and should not be used in medical literature without additional clarification.

Pelvic Organ Prolapse

Pelvic organ prolapse is the descent of ≥ 1 of the anterior vaginal wall, posterior vaginal wall, uterus, cervix, or apex of the vagina (or vaginal cuff after hysterectomy). This can occur with or without concomitant rectal prolapse. This can be quantified using the POP-Quantification system, which describes the relationship of the anterior and posterior walls of the vagina, the cervix, and the uterus in relationship to the vaginal hymen (Figs. 1A and B). The distance of each structure is marked in centimeters and

TABLE 1. Stages of the Pelvic Organ Prolapse-Quantification System Measurement

Stage	Description
Stage 0	No visible prolapse demonstrated.
Stage 1	The most distal portion of the prolapsing organ (posterior vagina, anterior vagina, cervix) is >1 cm above hymen.
Stage 2	The most distal portion of the prolapsing organ (posterior vagina, anterior vagina, cervix) is <1 cm above the hymen or at the hymen.
Stage 3	The most distal portion of the prolapsing organ (posterior vagina, anterior vagina, cervix) is ≥ 1 cm beyond the hymen but <2 cm.
Stage 4	Prolapse of >2 cm past the hymen or complete organ eversion.

labeled as negative when the organ is above the hymen or positive when the organ is below the hymen. Prolapse grades are assigned based on the degree of prolapse in relationship to the hymen (Table 1).

Perineal Descent

Perineal descent is the abnormal caudal movement of the pelvic floor with straining. It is measured clinically by the position of the anal verge in relationship to the plane of the ischial tuberosities at rest and during maximal straining. Normally, the anal verge lies just below an imaginary line drawn between the coccyx and the pubic symphysis. Perineal descent is diagnosed when the anus is observed to be several centimeters below this imaginary line at rest, with or without additional downward movement during straining.

Rectal Prolapse

Rectal prolapse is a circumferential, full-thickness intussusception of the rectal wall.⁵ The degree of prolapse can vary from intrarectal prolapse to intra-anal prolapse to external rectal prolapse, which can be additionally classified through the Oxford Prolapse Scale.⁶ External rectal prolapse can sometimes be visualized on the physical examination on patient straining. Sometimes clinical examination with the patient straining in the sitting position better visualizes the prolapse. Internal prolapse (intussusception) can only be demonstrated on defecography or proctoscopy.

Rectocele

A *rectocele* is a bulging of the rectum into the posterior wall of the vagina. Possible clinical symptoms include symptoms of rectal emptying difficulties, constipation, need to splint/digitate to facilitate rectal emptying, vaginal bulge, and fecal incontinence. Rectoceles can clinically be classified through the POP-Quantification system into 4 stages.⁷ This quantitative clinical description is based on the relationship between the mobile posterior vaginal wall and the anatomically fixed hymen (Table 1).

Slow Transit Constipation

Slow transit constipation is a subset of functional constipation in which patients report <1 bowel movement every 3 days. The presence and severity of STC are suspected and measured by querying patients on the degree of the decrease in their bowel movements, the extent of the loss of urge to defecate, the degree of need to use laxatives to assist a bowel movement, and the degree of bother caused by these symptoms.^{4,8} STC can coexist with other functional bowel disorders, such as obstructive defecation syndrome or IBS. Additional characterization and confirmation of STC require documentation of delayed colonic transit.

Definitions of Common Anorectal Physiology Testing Terminology

Anal Pressures

Evaluation of anal pressures is performed by placing a manometry catheter inside the anal sphincter, below the puborectalis. The *high-pressure zone* is the length of the anal canal with resting pressures $\geq 30\%$ higher than rectal pressure. *Resting pressure* is the pressure in the high-pressure zone at rest after a period of stabilization. *Maximum resting pressure* is the highest resting pressure recorded. *Mean resting pressure* is the mean of the resting pressures recorded within the high-pressure zone. *Maximum voluntary pressure* is the highest pressure recorded above the baseline (0) at any level of the anal canal during maximum squeeze effort by the patient. *Squeeze pressure* is the pressure increment above resting pressure after voluntary squeeze contraction and is a calculated value that is the difference between the maximum voluntary pressure and the resting pressure at the same level of the anal canal. *Cough pressure* is the pressure increment above resting pressure after a cough and is a calculated value that is the difference between the maximum pressure recorded during cough and the resting pressure at the same level in the anal canal. *Sphincter endurance* is the length of time that the patient can maintain a squeeze pressure above the resting pressure.

Anal Sensation

Anal sensation is the sensation in the anal canal measured by anal mucosal electrosensitivity. It reflects the somatic sensory component of the pudendal nerve.

Balloon Expulsion Test

The *balloon expulsion test* evaluates the ability of the patient to expel a balloon inflated with 50 to 60 mL of water. Patients with normal anorectal function are expected to expel the balloon.

Electromyography Recruitment

Electromyography recruitment records the change from basal electrical activity of motor units of the external anal

sphincter and levator muscles during muscle activity. This test is usually performed with surface electrodes or an intra-anal sponge with electrodes. Needle electrodes are painful and not used. Patients with normal anorectal function are expected to show a relaxation of the puborectalis when asked to push and a contraction of the puborectalis when asked to squeeze the anus closed.

Rectal Sensation

Evaluation of rectal sensation is performed by placing a balloon catheter above the anorectal ring. The balloon is gradually inflated with air.

Rectal pressure is the pressure generated by the rectum with rest, squeeze, and push. *Sensory threshold* is the minimum rectal volume perceived by the patient. *Urge sensation* is the volume associated with the initial urge to defecate. *Maximum tolerated volume* is the volume at which the patient experiences discomfort and an intense desire to defecate.

Definitions of Defecography Terminology

Defecography is a dynamic examination performed to study the anatomy and function of the anorectum and pelvic floor during defecation. Movement of pelvic structures in relationship to the pubococcygeal and ischiococcygeal lines and in relationship to each other are then described and quantified. These dynamic rectal emptying images can be captured with fluoroscopy, pelvic ultrasound, or MRI.

Dynamic Fluoroscopic Defecography

The rectum, and preferably also the vagina, are opacified with radiographic contrast. Sometimes other organs such as the small bowel and/or bladder are also opacified. The patient is asked to evacuate the rectal contrast into a radiolucent commode while dynamic images are captured fluoroscopically for additional analysis.

Dynamic MRI Defecography

The rectum is opacified with ultrasound gel. The patient is then asked to evacuate gel (supine or sitting) while the MRI captures dynamic evacuation images.

Dynamic Ultrasound Defecography

The rectum is opacified with ultrasound gel. The patient is then asked to evacuate gel (in lithotomy or in a left lateral decubitus position) while the ultrasonographer captures dynamic evacuation images with an intrarectal or a perineal ultrasound probe.

Anismus (Nonrelaxation of the Puborectalis and Paradoxical Contraction of the Puborectalis)

Anismus is defined by either the observation of a nonrelaxation of the puborectalis or actual paradoxical contraction of the puborectalis at the anorectal junction during evacuation.

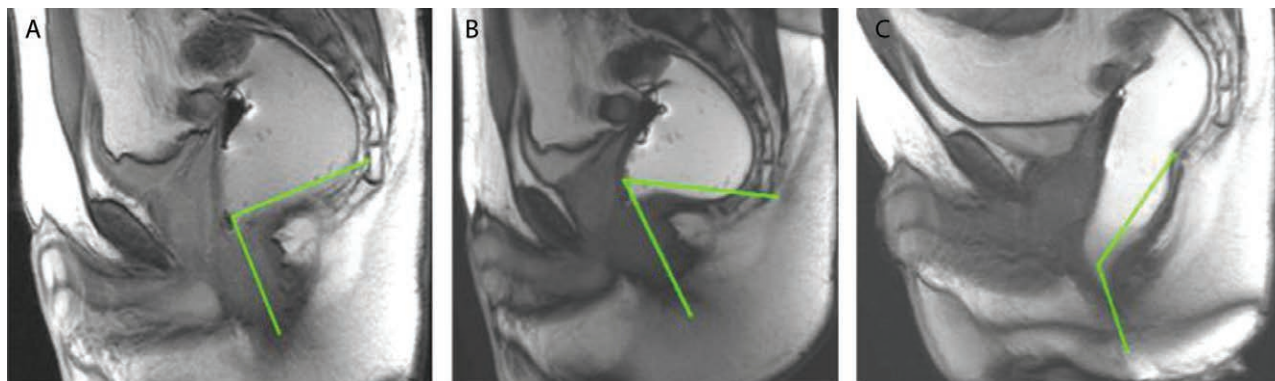


FIGURE 2. Anorectal angle. A, Images at rest: the anorectal angle is measured from the midline of the anal canal to a tangent to the posterior rectal wall. B, Images with squeeze: normally the anorectal junction narrows. C, Images with evacuation: normally the anorectal junction widens. Reprinted with permission from Magnetic Resonance Imaging Clinics of North America 2013;21:427–445.

Anorectal Angle

The *anorectal angle* is the angle created by a line drawn through the central axis of the anal canal and a line drawn through either the central axis of the distal rectum or a line drawn parallel to the posterior wall of the distal rectum (Fig. 2). It can be measured at rest and during evacuation. Normal values range from 90° to 110° at rest. Normal values increase at evacuation.

Enterocoele

On defecography, *enterocoele* is classified as small bowel present between the rectum and vagina, reaching lower than the upper third of the vagina during evacuation effort. A *first-degree enterocoele* is above the pubococcygeal line. A *second-degree enterocoele* is below the pubococcygeal line but above the ischiococcygeal line, and a *third-degree enterocoele* is below the ischiococcygeal line (Fig. 3). Alternatively, herniations of the peritoneal sac with contained peritoneoceles, omentocoeles, sigmoidocoeles, and enterocoeles can be graded as small (<3 cm), moderate (3–6 cm), and large (>6 cm) by measuring the largest distance between the pubococcygeal line and the most inferior point of the sac.

Ischiococcygeal Line

The *ischiococcygeal line* is a line extending from the inferior border of the ischium to the last coccygeal joint. It is drawn on defecography to serve as a landmark against which movement of pelvic organs is characterized.

Perineal Descent

Perineal descent is measured on defecography as the difference between the position of the anorectal junction at rest and during maximal straining in relationship to the pubococcygeal line. Additional measurements of the degree of descent can be generated with 2 additional reference lines (Fig. 4).

- H line* measures hiatal width. This measurement is taken from the inferior aspect of the symphysis pubis to the posterior wall of the rectum at the level of the anorectal junction.
- M line* measures the movement of the pelvic floor away from pubococcygeal line. This measurement is taken by extending a perpendicular line from the pubococcygeal line to the posterior end of the H line.
- Abnormal perineal descent* is present when the H line exceeds 6 cm and when the M line exceeds 2 cm in length (Fig. 5).

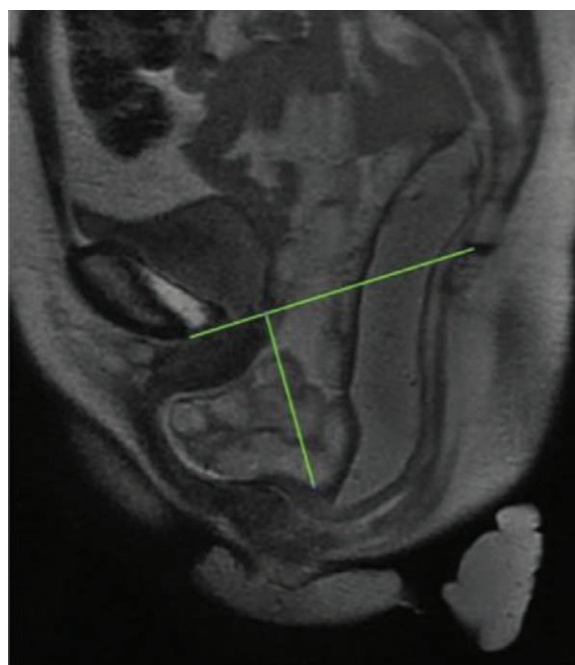


FIGURE 3. Pubococcygeal line, extending from the most inferior portion of the pubis symphysis to the last horizontal coccygeal joint. Descent of any particular structure is measured along a perpendicular line from the pubococcygeal line to the structure. This case shows a large enterocoele (grade 3). Reprinted with permission from Magnetic Resonance Imaging Clinics of North America 2013;21:427–445.

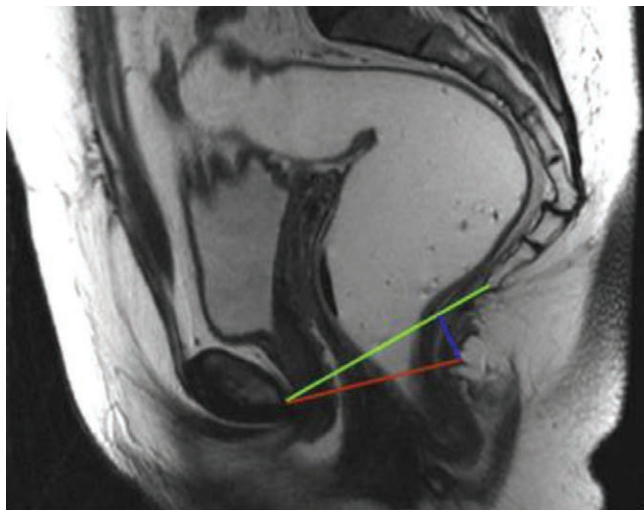


FIGURE 4. Pubococcygeal (green) line is the line drawn between the lower part of the pubis and the lowest coccygeal joint. H (red) line is the line drawn from the lower portion of the pubis symphysis to the posterior wall of the rectum. M (blue) line is the line drawn from the pubococcygeal line to the H line. Reprinted with permission from Magnetic Resonance Imaging Clinics of North America 2013;21:427–445.

Peritoneocele/Omentocele

On defecography, *peritoneocele* is a protrusion of the peritoneum between the rectum and the vagina that does not contain any abdominal viscera. A *first-degree peritoneocele/omentocele* is above the pubococcygeal line, a *second-degree peritoneocele/omentocele* is below the pubococcygeal line but is above the ischiococcygeal line, and a *third-degree peritoneocele/omentocele* is below the ischiococcygeal line. Alternatively, herniations of the peritoneal sac with contained peritoneoceles, omentoceles, sigmoidoceles, and enteroceles can be graded as small (<3 cm), moderate (3–6 cm), and large (>6 cm) by measuring the largest distance between the pubococcygeal line and the most inferior point of the sac.

Pubococcygeal Line

The *pubococcygeal line* is a line extending from the inferior border of the pubic symphysis to the last coccygeal joint that is drawn on defecography to serve as a landmark against which movement of pelvic organs is characterized (Figs. 3 and 4).

Rectocele

On defecography, a *rectocele* is a bulging of the rectal wall toward the vagina. A comment regarding its size and whether the rectocele empties with defecation with or without digitation can help to guide treatment. Radiographically, rectoceles are graded as small (<2 cm), moderate (2–4 cm), and large (>4 cm). Additional comment on the ability to empty with and without digitation can help guide therapy.

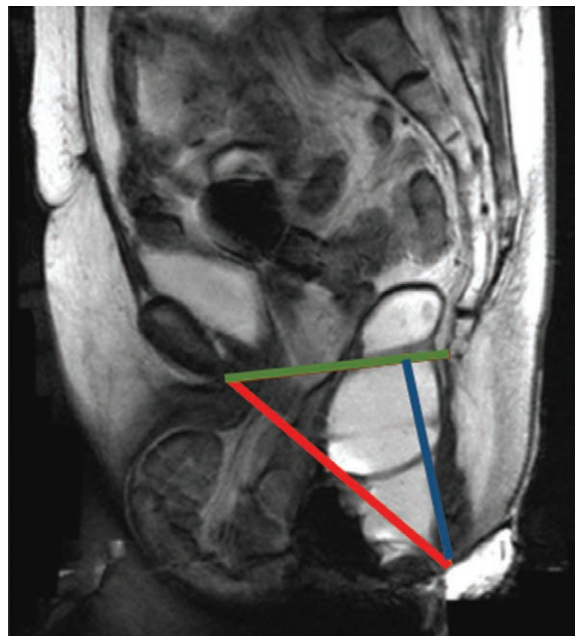

FIGURE 5. Perineal descent with a grade 3 enterocele (small bowel is below pubococcygeal line) and grade 4 vaginal prolapse (complete eversion). Also note that the H line (red) is widened and the M line (blue) is elongated. Image reprinted with permission from Magnetic Resonance Imaging Clinics of North America 2013;21:427–445.

Sigmoidocele

On defecography, *sigmoidoceles* are classified by the position of the lowest loop of the sigmoid during evacuatory effort. A *first-degree sigmoidocele* is above the pubococcygeal line, a *second-degree sigmoidocele* is below the pubococcygeal line but is above the ischiococcygeal line, and a *third-degree sigmoidocele* is below the ischiococcygeal line. Alternatively, herniations of the peritoneal sac with contained peritoneoceles, omentoceles, sigmoidoceles, and enteroceles can be graded as small (<3 cm), moderate (3–6 cm), and large (>6 cm) by measuring the largest distance between the pubococcygeal line and the most inferior point of the sac. Additional comment on the ability to empty with and without digitation and the degree of sigmoid redundancy can help to additionally guide therapy.⁹

REFERENCES

1. Lowry AC, Simmang CL, Boulos P, et al. Consensus statement of definitions for anorectal physiology and rectal cancer: report of the Tripartite Consensus Conference on Definitions for Anorectal Physiology and Rectal Cancer, Washington, D.C., May 1, 1999. *Dis Colon Rectum*. 2001;44:915–919.
2. Mearin F, Lacy BE, Chang L, et al. Bowel disorders. *Gastroenterology*. 2016;S0016-5085:00222–00225.
3. Altomare DF, Spazzafumo L, Rinaldi M, Dodi G, Ghiselli R, Piloni V. Set-up and statistical validation of a new scoring system for obstructed defaecation syndrome. *Colorectal Dis*. 2008;10:84–88.

4. Agachan F, Chen T, Pfeifer J, Reissman P, Wexner SD. A constipation scoring system to simplify evaluation and management of constipated patients. *Dis Colon Rectum*. 1996;39:681–685.
5. Brodén B, Snellman B. Procidentia of the rectum studied with cineradiography: a contribution to the discussion of causative mechanism. *Dis Colon Rectum*. 1968;11:330–347.
6. Collinson R, Cunningham C, D’Costa H, Lindsey I. Rectal intussusception and unexplained faecal incontinence: findings of a proctographic study. *Colorectal Dis*. 2009;11:77–83.
7. Bump RC, Mattiasson A, Bø K, et al. The standardization of terminology of female pelvic organ prolapse and pelvic floor dysfunction. *Am J Obstet Gynecol*. 1996;175:10–17.
8. Varma MG, Wang JY, Berian JR, Patterson TR, McCrea GL, Hart SL. The constipation severity instrument: a validated measure. *Dis Colon Rectum*. 2008;51:162–172.
9. Jorge JM, Yang YK, Wexner SD. Incidence and clinical significance of sigmoidoceles as determined by a new classification system. *Dis Colon Rectum*. 1994;37:1112–1117.